

## Annular Asymptomatic Plaques in a Diabetic Boy

†Samaneh Fazlolahi <sup>1</sup>, †Ifa Etesami <sup>1</sup>, Kambiz Kamyab <sup>2</sup>, Hamidreza Mahmoudi, <sup>1,3</sup> and Maryam Daneshpazhooh <sup>1,3\*</sup>

1. Department of Dermatology, Razi Hospital, Tehran University of Medical Sciences, Tehran, Iran

2. Department of Dermatopathology, Razi Hospital, Tehran University of Medical Sciences, Tehran, Iran

3. Autoimmune Bullous Diseases Research Center, Department of Dermatology, Tehran University of Medical Sciences, Tehran, Iran

†Samaneh Fazlolahi and Ifa Etesami made equal contribution to the manuscript.

### Case presentation

An 18-year-old boy with type 1 diabetes mellitus, presented to our dermatology clinic with a 3-year history of enlarging asymptomatic plaques on his legs, dorsum of hands and his abdomen. On physical examination two atrophic, yellowish plaques on left leg, one larger plaque on left ankle, an erythematous atrophic plaque on left hand and a smaller annular lesion on the abdomen were observed that had telangiectasias in the center and also peripheral elevated erythematous papules. The patient's diabetes was well-controlled and he did not show any sign of retinopathy, neuropathy or nephropathy. The patient was treated with topical tacrolimus 0.1% and intralesional steroid in the margin.

### Discussion

Multiple arborising telangiectatic vessels, intermixed with thin hair-pin-like vessels were seen on a mixed pink, white and yellowish background on dermoscopy (Figure 1).

A skin biopsy revealed layers of granulomatous lymphohistiocytic infiltrations and alternating necrobiosis and fibrosis, which were compatible with Necrobiosis Lipoidica (NL).

NL is a non-infectious granulomatous disease of the skin that usually presents as shiny atrophic telangiectatic yellow-brown plaques on the shins <sup>1</sup> (Figure 2). Women are more commonly affected than men. NL lesions are often painless but they could be painful if ulcerated <sup>2</sup>. NL is histologically characterized by collagen degeneration and thickening of blood vessels. It is seen among 0.3-1.2% of all diabetic patients; while nearly two thirds of patients with NL have diabetes <sup>1</sup>. NL is more commonly diagnosed after the diabetes, but it may precede diabetes or happen concurrently. Although the exact pathogenic mechanism is not yet clear, many patients with both diabetes and NL were shown to have poor glycemic control, so a microangiopathic etiology for the development of these skin lesions have been proposed <sup>3</sup>. The main dermoscopic find-

### \*Corresponding author

**Maryam Daneshpazhooh, MD**

Department of Dermatology, Razi Hospital, Vahdate-Eslami Square, Tehran 11996, Iran.

**Tel:** +98 21 5561 8989

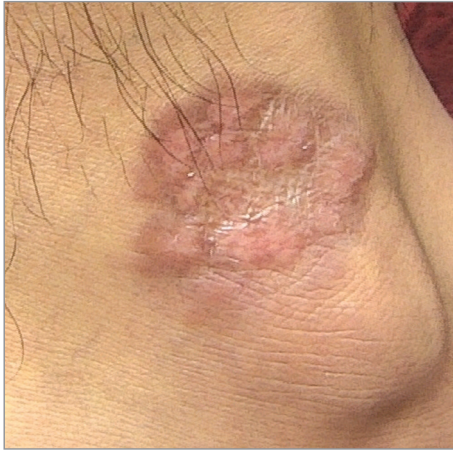**Fax:** +98 21 5561 8989

**Email:** daneshpj@tums.ac.ir

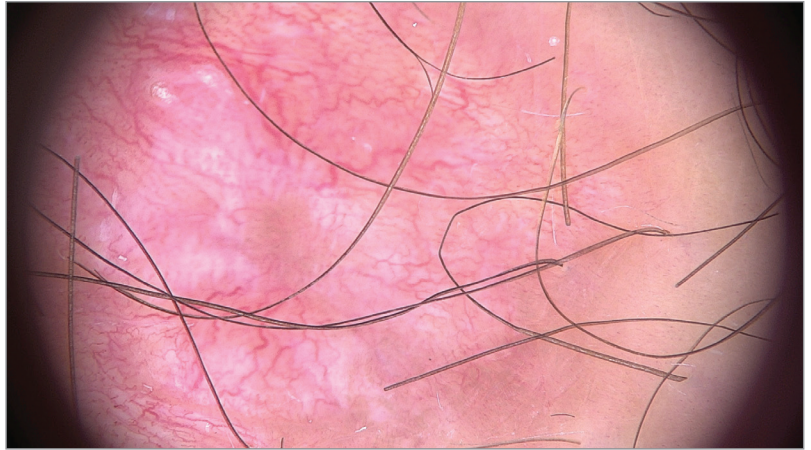
**Received:** 18 May 2018

**Accepted:** 29 May 2018

**Citation to this article:** Fazlolahi S, Etesami I, Kamyab K, Mahmoudi H, Daneshpazhooh M. Annular Asymptomatic Plaques in a Diabetic Boy. *JIMC*. 2018;1(1):43-44.



**Figure 1.** Necrobiosis lipoidica: Yellow-brown papules arranged at the periphery of an atrophic depressed area.



**Figure 2.** Necrobiosis lipoidica: Multiple arborizing telangiectatic vessels and thin hairpin-like vessels on a mixed pink, white and yellowish background on dermoscopy with Fotofinder Video Dermatoscope Videocam 1000.

ings of NL are the presence of branching telangiectasias, hairpin-like vessels, and a yellowish background<sup>4,5</sup>. Dermoscopy may be helpful for differentiating NL from other granulomatous disorders<sup>4,5</sup>. Therapeutic modalities such as topical and intralesional steroids,

topical tacrolimus, cyclosporine, mycophenolate mofetil, ASA and clofazimine have had limited success<sup>2</sup>, but improvement in glycemic control may particularly lead to NL resolution in type-1 diabetic patients<sup>3</sup>.

## References

1. Lima AL, Illing T, Schliemann S, Elsner P. Cutaneous manifestations of diabetes mellitus: A review. *Am J Clin Dermatol*. 2017;18(4):541-553.
2. Reid SD, Ladizinski B, Lee K, Baibergenova A, Alavi A. Update on necrobiosis lipoidica: a review of etiology, diagnosis, and treatment options. *J Am Acad Dermatol*. 2013;69(5):783-791.
3. Mistry BD, Alavi A, Ali S, Mistry N. A systematic review of the relationship between glycemic control and necrobiosis lipoidicadiabeticorum in patients with diabetes mellitus. *Int J Dermatol*. 2017;56(12):1319-1327.
4. Pellicano R, Caldarola G, Filabozzi P, Zalaudek I. Dermoscopy of necrobiosis lipoidica and granuloma annulare. *Dermatology*. 2013;226(4):319-323.
5. Ramadan S, Hossam D, Saleh MA. Dermoscopy could be useful in differentiating sarcoidosis from necrobiotic granulomas even after treatment with systemic steroids. *Dermatol Pract Concept*. 2016;6(3):17-22.