



# Bilateral Aplasia of the Frontal, Sphenoid and Maxillary Sinuses and Unilateral Aplasia of the Ethmoid Air Cells

Parisa Soltani<sup>1</sup>, Mahnaz Sheikhi<sup>2</sup>, Mahsayeh Lashkarizadeh<sup>3\*</sup>, Flavia Iaculli<sup>4</sup> and Gianrico Spagnuolo<sup>4</sup>

1. Department of Oral and Maxillofacial Radiology, Dental Implants Research Center, Dental Research Institute, School of Dentistry, Isfahan University of Medical Sciences, Isfahan, Iran

2. Department of Oral and Maxillofacial Radiology, Dental Research Center, Dental Research Institute, School of Dentistry, Isfahan University of Medical Sciences, Isfahan, Iran

3. Department of Oral and Maxillofacial Radiology, Faculty of Dentistry, Kurdistan University of Medical Sciences, Sanandaj, Iran

4. Department of Neurosciences, Reproductive and Odontostomatological Sciences, University of Naples "Federico II", Naples, Italy

## \* Corresponding author

### Mahsayeh Lashkarizadeh, DDS

Department of Oral and Maxillofacial Radiology, Faculty of Dentistry, Kurdistan University of Medical Sciences, Sanandaj, Iran

Tel/Fax: +98 87 3366 8921

Email: mahsayeh.lashkarizadeh@muk.ac.ir

Received: Aug 29 2021

Accepted: Feb 23 2022

## Citation to this article:

Soltani P, Sheikhi M, Lashkarizadeh M, Iaculli F, Spagnuolo G. Bilateral Aplasia of the Frontal, Sphenoid and Maxillary Sinuses and Unilateral Aplasia of the Ethmoid Air Cells. J Iran Med Council. 2022;5(3):532-36.

## Abstract

**Background:** Sporadic cases of sinus aplasia have been reported in the literature, but only a few cases of total aplasia of paranasal sinuses have been recorded. In this report, we aim to present a case of aplasia of all paranasal sinuses except for the right ethmoid sinus which was hypoplastic.

**Case Report:** The patient was a 50-year-old female referred for obtaining Cone Beam Computed Tomography (CBCT) prior to dental implant placement. The patient was asymptomatic and did not have any complaints or discomforts associated with the craniofacial structures. CBCT views showed bilateral absence of paranasal sinuses. Only two ethmoid air cells were detected on the right side.

**Conclusion:** This is the first case report for aplasia considering paranasal sinuses except for right ethmoid cells which were hypoplastic in Iranian population.

**Keywords:** Cone-beam computed tomography, Dental implants, Ethmoid sinus, Iran, Paranasal sinuses

## Introduction

Paranasal sinuses are air-filled structures in the facial skeleton. They originate from evaginations from the nasal fossa into the surrounding bones during the third and fourth fetal months and tend to expand accompanying facial growth afterwards (1). Although functions of the paranasal sinuses are not clear, contributing to the vocal resonance, humidification and warming of the inspired air, thermal insulation and protection of the brain, lightening of the skull and facial bones and distribution of masticatory forces are considered as some of the roles for these air-filled cavities (2,3).

The exact causes of aplasia of the paranasal sinuses have not been completely understood yet. Each sinus enlarges in the medullary space of the representative bone. Developmental failures, infections, irradiation and hormonal disturbances can interfere with this process and result in hypoplasia or aplasia of sinuses (2,4). This report presents the first case in Iranian population, showing bilateral absence of paranasal sinuses with no signs of discomfort or syndromes. Only two ethmoid air cells were detected on the right side.

## Case Presentation

A 50-year-old Iranian woman attended School of Dentistry, Isfahan, Iran for dental implant treatment and was referred by the oral and maxillofacial surgeon for Cone Beam Computed Tomography (CBCT). Clinically, lack of malar prominence, maxillary deficiency and hypernasal speech were noted (Figure 1). The patient had no complaints of headache, hearing problems, nasal obstruction, nasal discharge, facial pressure and tiredness. She neither had any mastication problems nor a history of irradiation or trauma. The patient reported taking levothyroxine, hydroxychloroquine, diltiazem, aspirin, atorvastatin, nortriptyline, omeprazole, fluoxetine, prednisolone, and calcium, vitamin D, iron, and folic acid supplements. All laboratory tests were normal except inorganic phosphorus level which was slightly above the normal range.

CBCT scans of both jaws were obtained by Galileos (Sirona Dental Systems GmbH, Bensheim, Germany) with exposure parameters of 85 kVp and 35 mAs, field of view of 15×15 cm and voxel size of 280

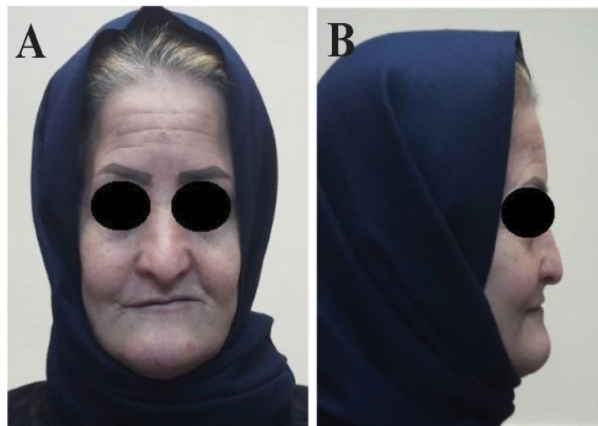
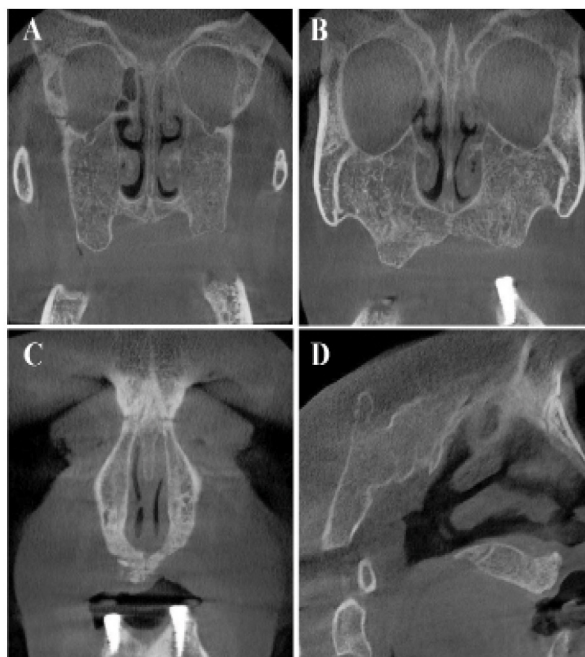


Figure 1. A) frontal and B) profile photographs.

*um*. Evaluation of coronal, axial and sagittal views revealed absence of pneumatization of the paranasal sinuses; although only two ethmoid air cells were noted on the right side. Nasal cavity, septum, conchae and lateral nasal wall appeared normal (Figure 2). Clinical examination as well as paraclinical examinations ruled out presence of systemic diseases affecting body skeleton such as Paget's disease, cretinism, thalassemia, or other syndromes. Genetic examination revealed a normal karyotype. There was no familial history of sinus agenesis. As the patient was asymptomatic, no further treatment option was required and the standard presurgical images for placement of dental implants were prepared.

## Discussion

Development of paranasal sinuses can be adversely affected by conditions such as trauma, neonatal tumors, irradiation, hypothyroidism, primary ciliary dyskinesia, cystic fibrosis, infections, bone dysplasia and syndromes including Down syndrome, Apert syndrome, Crouzon syndrome, Treacher Collins syndrome, Schwartz-Lelek syndrome and Prader-Willi syndrome (2,4,5). Sinus aplasia is a rare phenomenon occurring more frequently in frontal and maxillary and seldom in sphenoid sinuses (6). Case reports of total aplasia of paranasal sinuses are extremely rare. Agenesis of the paranasal sinuses is an uncommon clinical condition that appears mainly in the frontal (12%) and maxillary (5-6%) sinuses (7,8) mostly unilaterally (9). In addition, unilateral absence of ethmoid sinus is reported as a rare case (10). Assiri *et al* demonstrated an incidence of



**Figure 2.** Cone beam computed tomographic views. A) coronal view depicting aplasia of the left ethmoid air cells and two ethmoid air cells on the right side, B) coronal view depicting bilateral aplasia of maxillary sinuses, C) coronal view depicting aplasia of frontal sinuses, and D) sagittal view depicting aplasia of the sphenoid sinuses.

bilateral frontal sinus aplasia of 3.3% among Saudi Arabian population; conversely, monolateral agenesis had an incidence of 5.12 and 1.33% for right and left sinus, respectively (11). In the same way, Jordanian population showed a prevalence of bilateral frontal sinus aplasia of 4.2% and unilateral frontal sinus aplasia of 6.6% (12). These results are slightly higher than that observed among Turkish population of 0.73 and 1.22% concerning bilateral and unilateral absence of the frontal sinuses, respectively (7).

Sinus aplasia may cause chronic headaches, facial fullness, nasal drip, and voice problems. However, patients may be asymptomatic, thus sinus aplasia can be an incidental finding detected by maxillofacial radiologists (13,14). Diagnosing aplasia or hypoplasia of paranasal sinuses can be important for a variety of reasons. Failure in development of paranasal sinuses can be a sign for underlying significant medical conditions. In addition, small or absent paranasal sinuses must be reported prior to any endoscopic sinus surgery or transsphenoidal hypophysectomy to prevent injuries to vital structures (15-17).

Bilateral paranasal sinus aplasia is an extremely

rare condition and to our knowledge, there are few case reports of this anomaly: In 2012, Celebi *et al* presented a 35-year-old man with complaints of nasal obstruction and fullness of the face. He had a normal appearance without any associated disease or anomalies. Computed tomography (CT) revealed aplasia of all paranasal sinuses (4). In 2013, Korkmaz *et al* reported a 57-year-old female patient who complained of nasal stuffiness, frequent headaches and hearing loss during headache attacks. On CT examination, absence of all paranasal sinuses was noted (3). In 2013, Kandogan *et al* reported aplasia of maxillary, sphenoid and frontal sinuses and hypoplasia of both ethmoid sinuses in CT images of a 23-year-old male with complaints of nasal obstruction and headache (1). In 2015, Joshi *et al* reported a 15-year-old Hindu male patient with complaints of bilateral headache, facial fullness and postnasal discharge. Clinical examination showed lack of malar prominences. CT revealed aplasia of all paranasal sinuses (18). In 2017, Joshi *et al* reported a 7-year-old male child who was mentally disabled. Hypoplasia of cerebellar vermis, dilated IV ventricle

and mega cistern magna were revealed in CT. He was diagnosed with Dandy-Walker malformation (6). Takaichi *et al* in 2020 presented a case of total aplasia of paranasal sinuses and multiple impacted teeth in a nonsyndromic 77-year-old male based on CT imaging and paraclinical examinations (19).

Our case presented the first case of aplasia of all paranasal sinuses, except for the right ethmoid sinus which was hypoplastic in Iranian population.

The condition was diagnosed on CBCT images obtained for presurgical evaluation of alveolar bones for placement of dental implants. CBCT can be used effectively for diagnosing developmental abnormalities in the craniofacial skeleton (20-23).

### Conflict of Interest

There was no conflict of interest for the authors in this study.

## References

1. Kandogan T, Dalgic A, Mollamehmetoglu H, Esen O. Combined aplasia of sphenoid, frontal, and maxillary sinuses with hypoplasia of the ethmoid sinus. *Iran Red Crescent Med J* 2013 Jan;15(1):13-4.
2. Som PM, Curtin HD. *Head and neck imaging*. 5th ed. The US: Elsevier Health Sciences; 2011. 3080 p.
3. Korkmaz H, Korkmaz M. Total aplasia of the paranasal sinuses. *Allergy Rhinol* 2013 Summer;4(2):e105-9.
4. Celebi S, Taskin U, Altın F, Ozkul MH. Bilateral aplasia of paranasal sinuses. *Eur Arch Otorhinolaryngol* 2012 Mar;269(3):1055-7.
5. Ozcan KM, Hizli O, Sarisoy ZA, Ulusoy H, Yildirim G. Coexistence of frontal sinus hypoplasia with maxillary sinus hypoplasia: a radiological study. *Eur Arch Otorhinolaryngol* 2018 Apr;275(4):931-5.
6. Joshi A, Joshi R. A rare case report of total aplasia of paranasal air sinuses with posterior fossa malformation (Dandy Walker). *IAIM* 2017;4:250-7.
7. Çakur B, Sumbullu MA, Durna NB. Aplasia and agenesis of the frontal sinus in Turkish individuals: a retrospective study using dental volumetric tomography. *Int J Med Sci* 2011 Apr 8;8(3):278-82.
8. Papadopoulou AM, Chrysikos D, Samolis A, Tsakotos G, Troupis T. Anatomical variations of the nasal cavities and paranasal sinuses: a systematic review. *Cureus* 2021 Jan 15;13(1):e12727.
9. Steier L, Steier G, Doğramacı EJ, Rossi-Fedele G. Maxillary sinus unilateral aplasia as an incidental finding following cone-beam computed (volumetric) tomography. *Aust Endod J* 2014 Apr;40(1):26-31.
10. Felix V, Veerasigamani N. Unilateral absence of ethmoid sinus and nasal turbinates: a rare case report. *J Clin Diagn Res* 2017 Apr;11(4):MD01-MD02.
11. Assiri KS, Alroqi AS. Frequency of the frontal sinus aplasia among Saudi Arabian population. A single-center retrospective case review. *Saudi Med J* 2021 Feb;42(2):228-31.
12. Al-Balas HI, Nuseir A, Alzoubi F, Alomari A, Bani-Ata M, Almehzaa S, et al. Prevalence of frontal sinus aplasia in Jordanian individuals. *J Craniofac Surg* 2020 Oct;31(7):2040-2.
13. Thiagarajan B, Narashiman S. Hypoplasia of all paranasal sinuses A case series and literature review. *Otolaryngol Online J* 2012;2(2):1-5.
14. Duzer S, Aydemir Y, Sakallioğlu O, Akyigit A, Polat C, Cetiner H. Significance of paranasal sinus aplasia. *Acta Med Mediterranea* 2017 Jan 1;33(4):637-40.
15. Keskin G, Üstündag E, Ciftci E. Agenesis of sphenoid sinuses. *Surg Radiol Anat* 2002 Dec;24(5):324-6.
16. Tatlıpınar A, Dede O, Esen E, Gökçeer T, Akoğlu T. Combined sphenoid and frontal sinus aplasia accompanied

- by bilateral maxillary sinus hypoplasia in a child with sinusitis. *Int J Pediatr Otorhinolaryngol Extra* 2011 Sep 1;6(3):149-52.
17. Nayak DR, Balakrishnan R, Murty KD. Functional anatomy of the uncinata process and its role in endoscopic sinus surgery. *Indian J Otolaryngol Head Neck Surg* 2001 Jan;53(1):27-31.
18. Joshi A, Sundarray C, Sahoo KA. Bilateral total aplasia of paranasal sinuses: a rare case report. *Clin Rhinol An Int J* 2015 Dec 1;8(3):124-6.
19. Takaichi M, Tomihara K, Terashima R, Ichijo H, Kamisaki Y, Fujiwara K, et al. Total paranasal sinus aplasia with multiple impacted teeth: A case report. *J Oral Maxillofac Surg Med Pathol* 2021 Mar 1;33(2):158-60.
20. Kochhar AS, Sidhu MS, Prabhakar M, Bhasin R, Kochhar GK, Dadlani H, et al. Intra- and interobserver reliability of bone volume estimation using OsiriX software in patients with cleft lip and palate using cone beam computed tomography. *Dent J* 2021 Jan 22;9(2):14.
21. Nikkerdar N, Eivazi N, Lotfi M, Golshah A. Agreement between cone-beam computed tomography and functional endoscopic sinus surgery for detection of pathologies and anatomical variations of the paranasal sinuses in chronic rhinosinusitis patients: a prospective study. *Imaging Sci Dent* 2020 Dec;50(4):299-307.
22. Kiss P, Taucher V, Wolf A, Moser UC, Andrianakis A, Kirnbauer B. Cone beam computed tomography—measuring image quality of paranasal sinus imaging. A low-radiation alternative to conventional computed tomography? *Laryngorhinootologie* 2020 May;99(S 02).
23. Kabak SL, Savrasova NA, Zatochnaya VV, Melnichenko YM. Hemifacial microsomia: skeletal abnormalities evaluation using CBCT (case report). *J Radiol Case Rep* 2019 Nov 30;13(11):1-9.